

Introduktion Ortopedi

Lars Weidenhielm
Ortopedkliniken
KS

Schema Patientdemonstration Kurslitteratur Tentamen (tentavakter T4)

Lindgren U. Svensson O. Ortopedi.
Almqvist & Wiksell, Medicin/Liber. 1996.
alternativt
Graham Apley A. Solomon Louis. Concise
System of Orthopedics and Fractures.
Oxford: Butterworth-Heinemann Ltd, 1994.

Ortho - Paidion

Grekiska *Orthos* = rak och *Pais* = barn

Historik

- ”Ortopedins fader” Nicholas Andry 1741
- Anestesi 1846 – Morton
- Aseptik 1865 – Lister
- Röntgen 1895 – Röntgen
- Metallurgi 1930
- Antibiotika – 1935 sulfa, 1945 penicillin

Ortopedi - medfödda och förvärvade skador och sjukdomar i rörelseapparaten

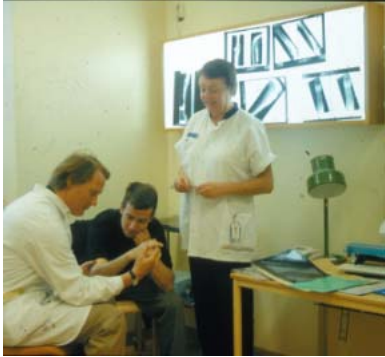- Alla åldrar
- Alla delar

- 30% av alla besök i primärvården

Sjukgymnasten - Ortopeden



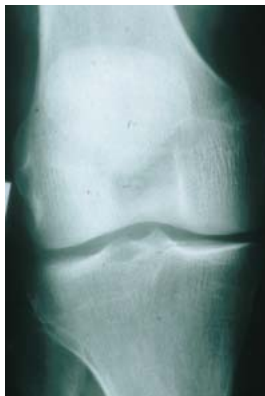Frakturmottagningen



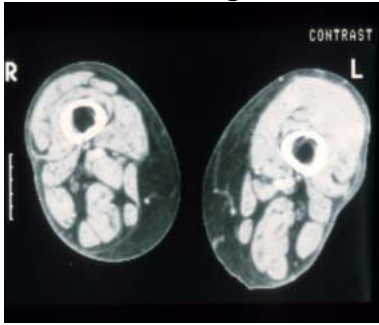
Diagnostik

- Anamnes – Smärta
- Undersökning
- Röntgen (Datortomografi, MR)
- Artroskopi

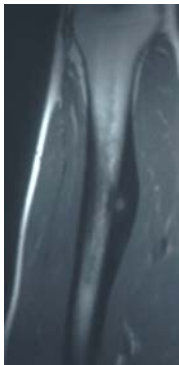Slätrtg



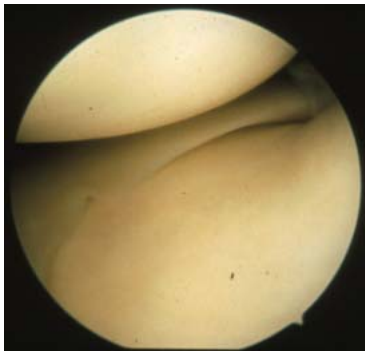
Datortomografi



MR - Magnet Resonans Tomografi

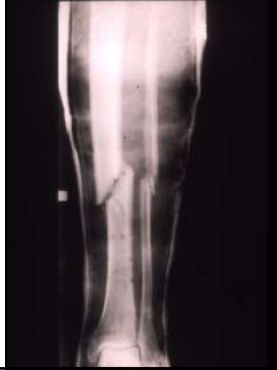

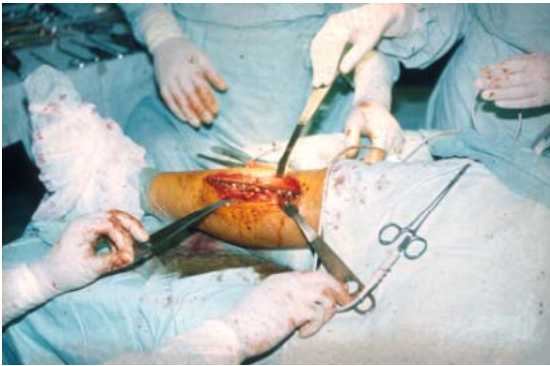
Artroskopi

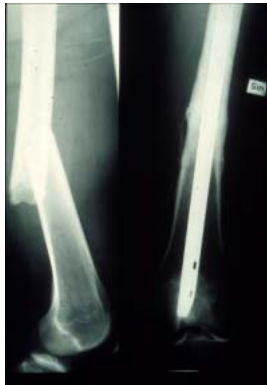
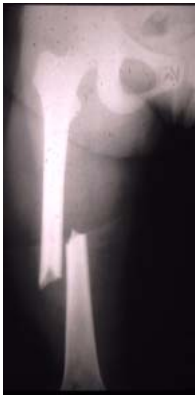
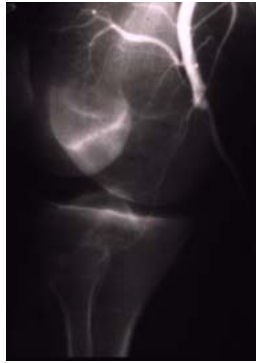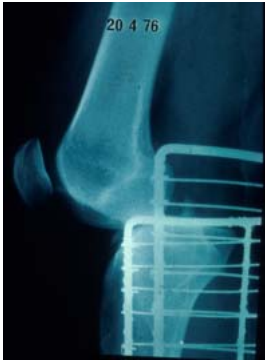Nedre Extremiteten

Underbens-
fraktur

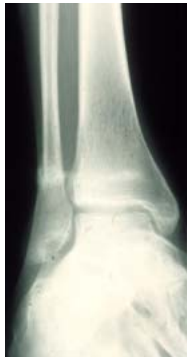




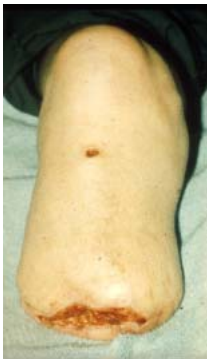


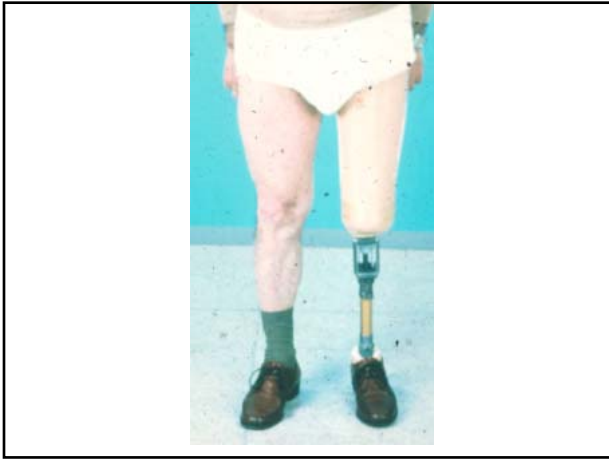Stressfraktur

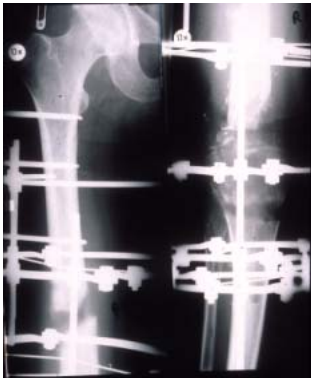

Amputationsstump





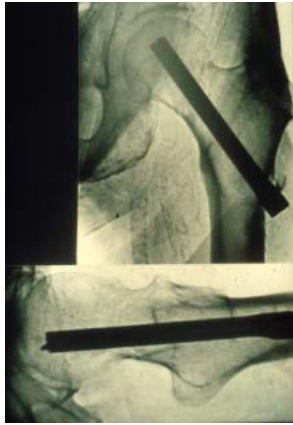Benförlängning



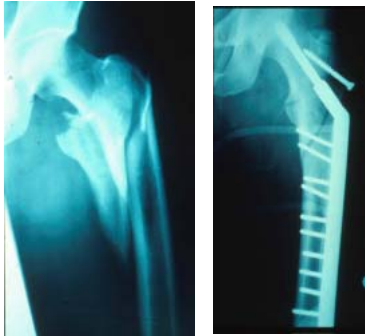Höftfraktur

- Medial collumfraktur
- Pertrockantär femurfraktur

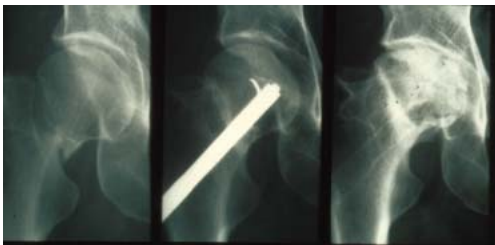Medial
collumfraktur



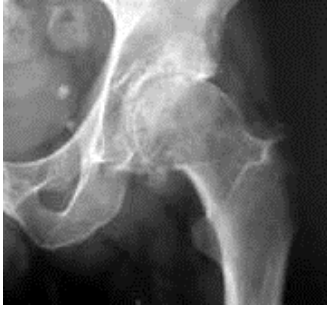Petrockantär femurfraktur



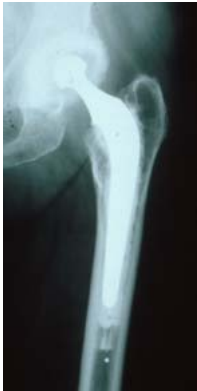Caputnekros



Coxartros



Cementerad höftprotes (Charnley)



Arthroplasty of the Hip

22 months has shown negligible wear. The stresses imposed on the hip-joint of patients operated by arthroplasty are only a fraction of those borne by the hip-joint of normal subjects on ordinary locomotion if the method could prove suitable for other patients in similar cases. It may have a particular place in the treatment of the rheumatoid joint, the elderly, low when it is particularly suitable, because it requires almost no rehabilitation. Even in the early stages there is no pain on movement, and the procedure is suitable for subjects with the poor muscle and relatively feeble nerves which so often accompany long-standing rheumatoid arthritis in old age.

ACKNOWLEDGMENTS
I am indebted to the Manchester Regional Hospital Board, which has established at Withington the centre for the surgery of the hip-joint, at which

the clinical work described in this paper has been done. In the general ideas behind this paper I have been inspired by several sources. I am indebted to the researches of Sir Donald Johnston, F.R.C.S., in arthroplasty and that of Sir Charles Huggles, F.R.C.S., in the use of the cemented acetabulum. Mr. Huggles and his colleagues at the Royal Infirmary, Manchester, have all made the original progress. With advice from the surgeons, Department of Radiology, at Withington, I took the 'top' and film division for obtaining different types of roentgen in weight of view.

REFERENCES

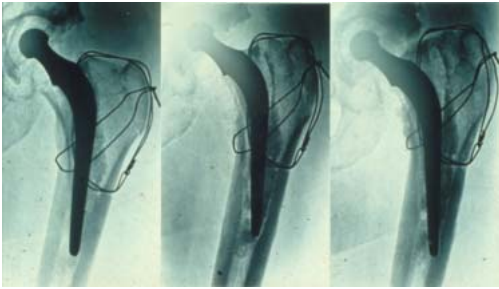1. Charnley, J. Institution of Mechanical Engineers. Symposium on Arthroplasty, April 17, 1959, p. 12.
2. Jones, E. S.; Latham, J. 1926, 1934.
3. Jones, E. S.; Latham, J. 1945, 1948.
4. Jahn, J. and Jahn, R. J. Bone Joint Surg., 1938, 20, 1043.
5. Smith-Petersen, M. N. J. Bone Joint Surg., 1938, 20, 1048.



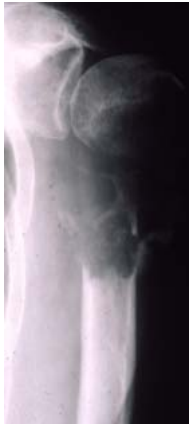JOHN CHARNLEY

John Charnley (1911) - J.C.B.E., F.R.C.S., Professor of Orthopaedic Surgery, University of Manchester, Director, Centre for Hip Surgery, Withington Hospital, was the effective pioneer of the arthroplasty procedure known in English medical writings as total hip replacement. There is of course a century and a half of joint reconstructive surgery behind this. Charnley's principal contribution must be considered the efficient development of a self-caring acrylic cement to anchor both the femoral replacement and the acetabulum acrylic or metal socket. This 1961 report on the Lower was suggested by John Charnley in a personal communication to me on seeing his most important early contributions to total hip replacement.

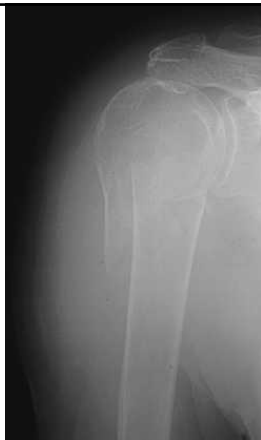Proteslossning



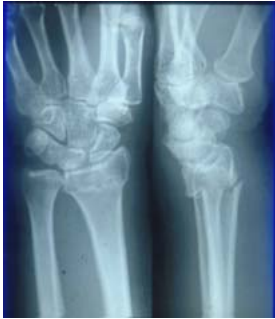Övre Extremiteten



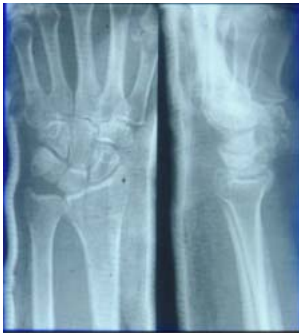Collum chirurgicum fraktur



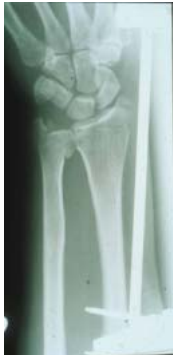Radiusfraktur



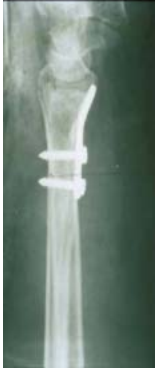Radiusfraktur - gips



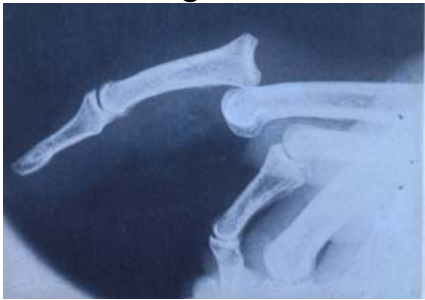Radiusfraktur - externfixation



Radiusfraktur - internfixation



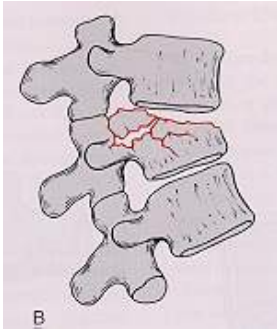Fingerluxation



Ryggen



Kotfraktur



Metastas i kota